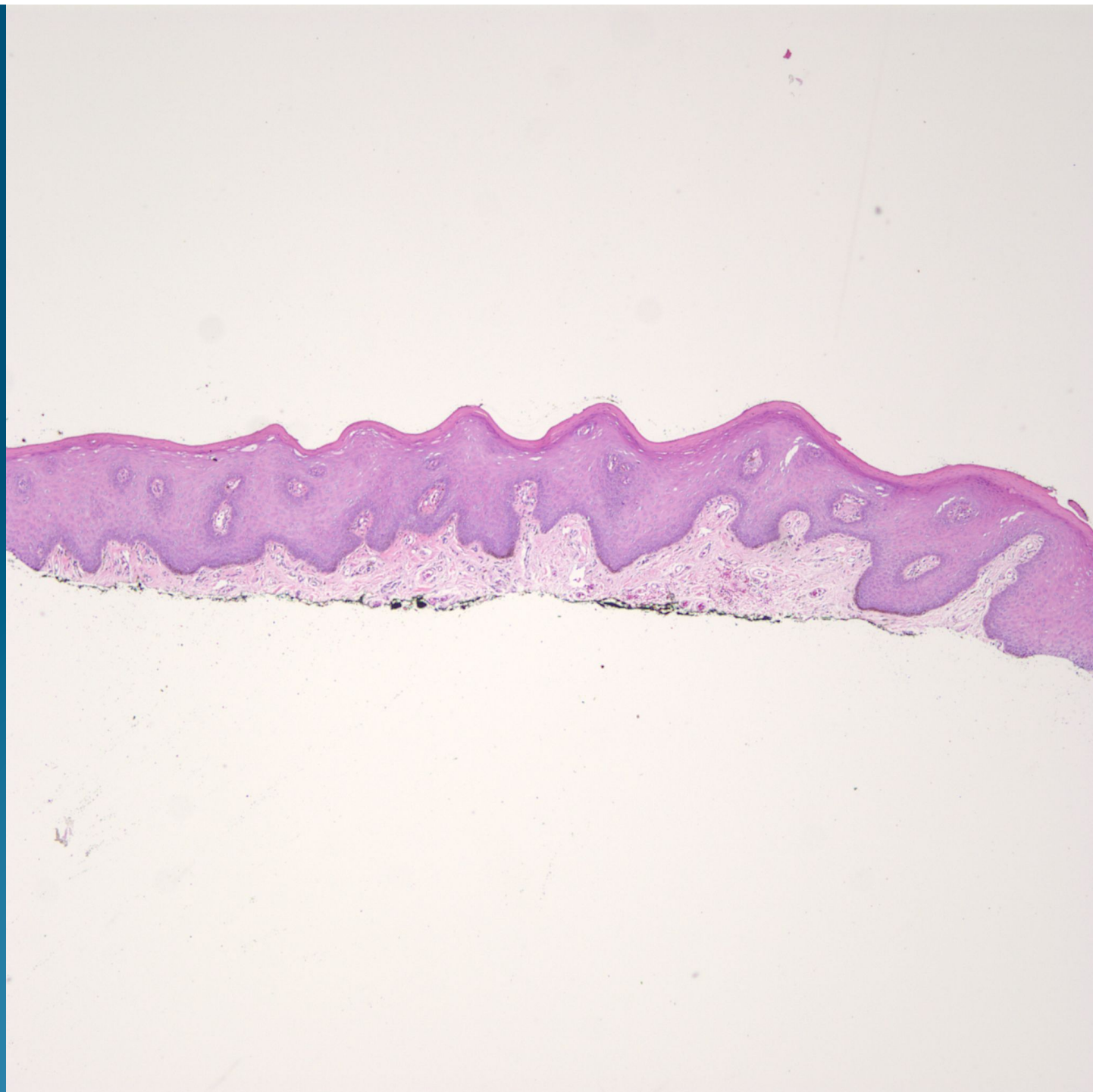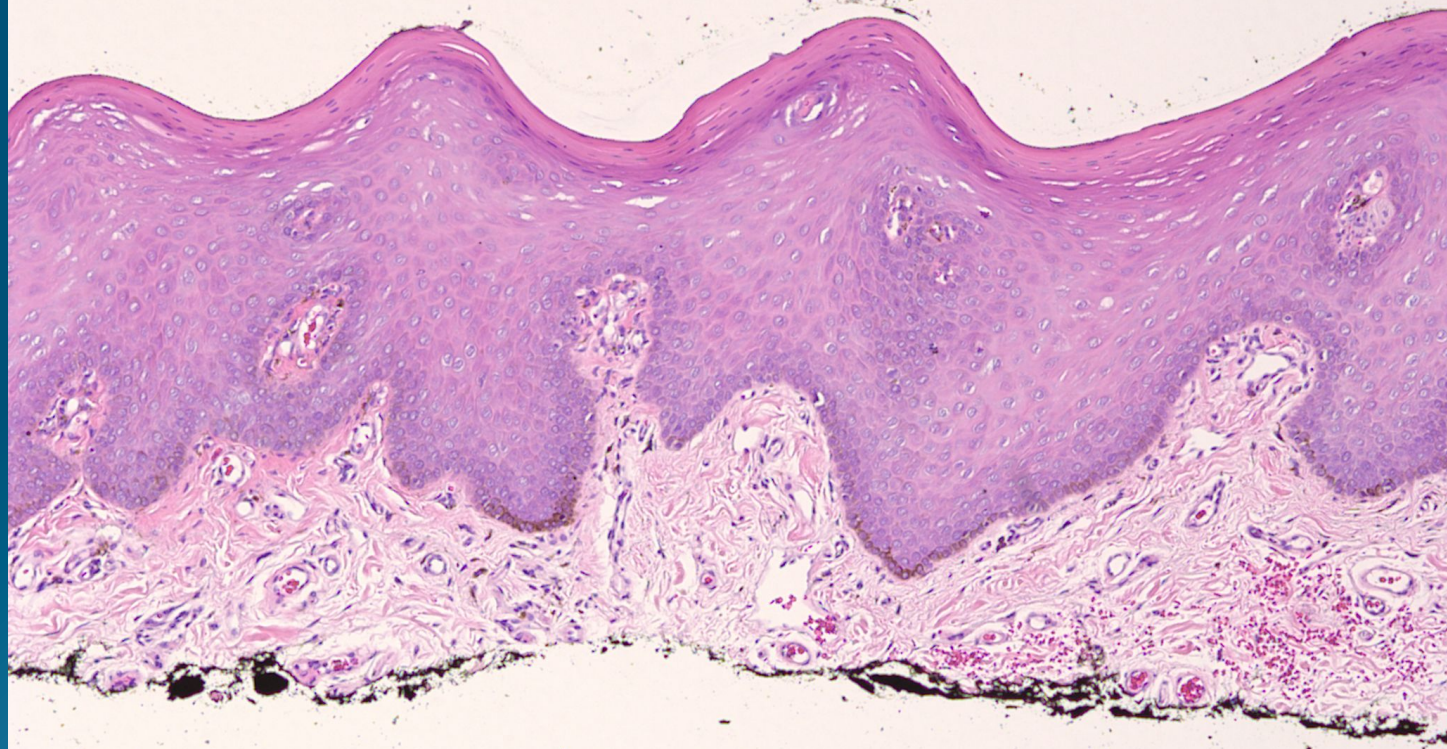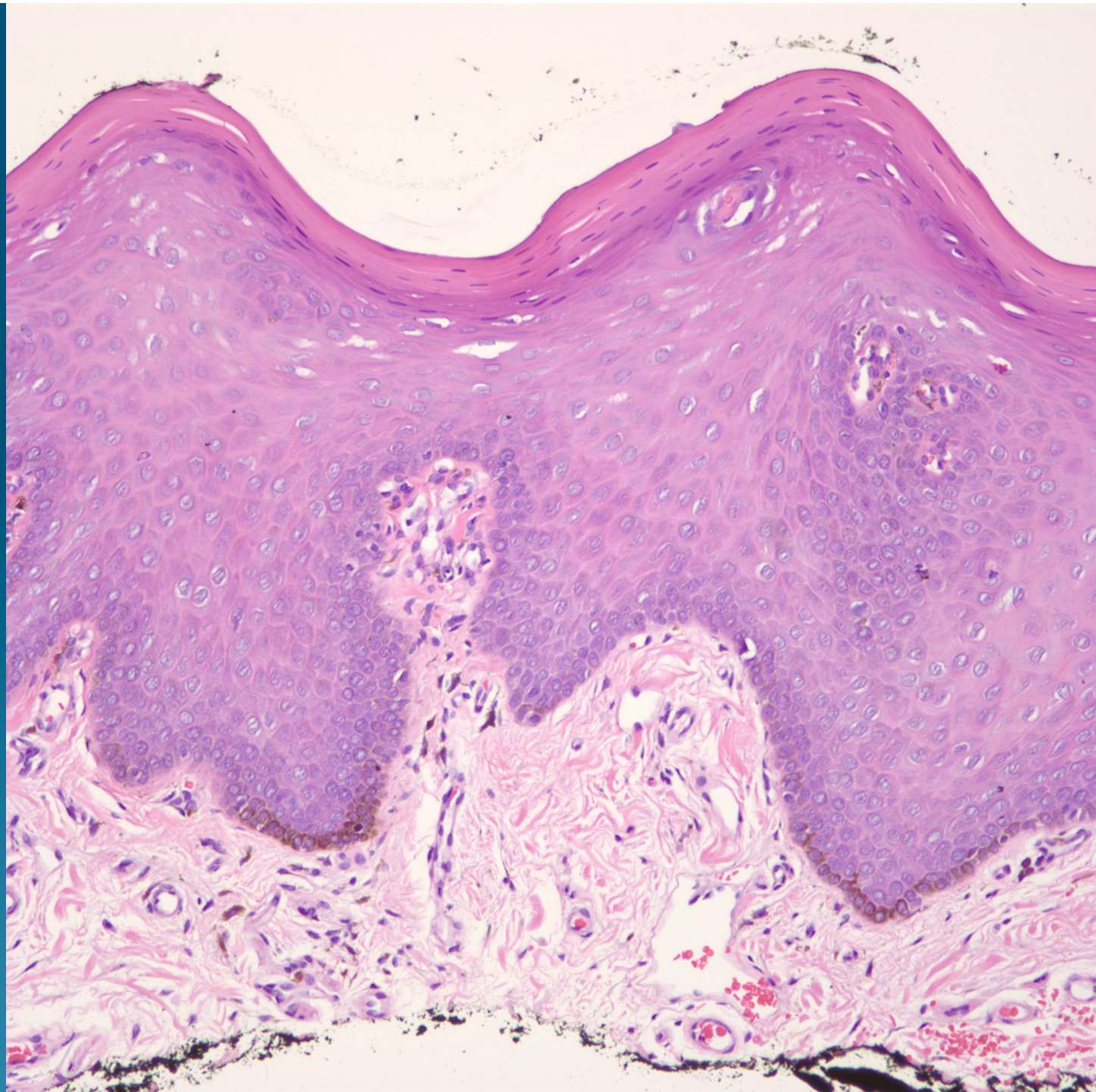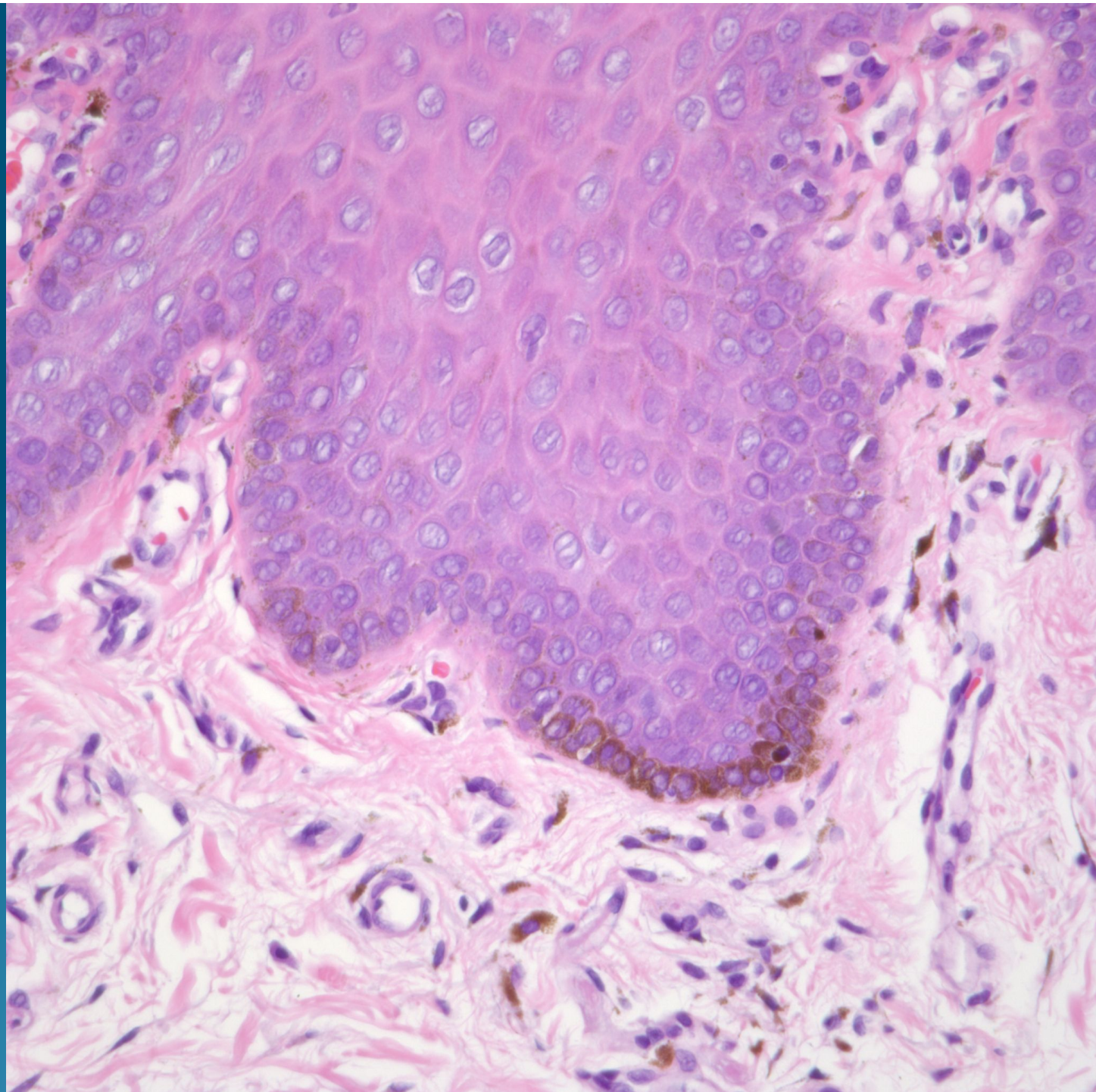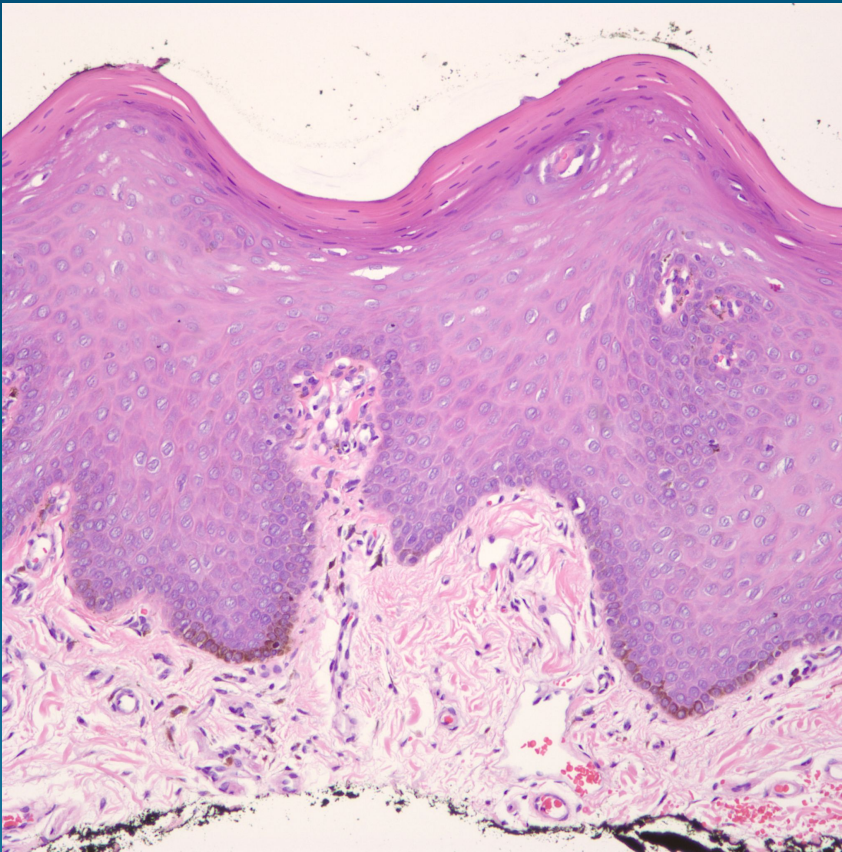


Mucosal Lentigo (Labial Melanotic Macule)

Pearls



- Recognize mucosal squamous epithelium
- Continuous increase in melanin pigment at the mucosal-submucosal junction
- No cytologic atypia of the melanocytes